



ICASH-A010

THE EFFECTIVENESS OF LEMON JUICE (*Citrus limon*) TOWARD PYRAMIDAL NEURON CELLS OF MALE WHITE MICE'S CEREBRAL CORTEX THAT EXPOSED BY MONOSODIUM GLUTAMATE (MSG)

Pepi Arifiyani*, Hikmah Fitriani, Rachmanda Haryo Wibisono

Faculty of Medicine, Universitas Swadaya Gunung Jati, Cirebon, Indonesia

*Corresponding author's email: pepiarifiyani@gmail.com

ABSTRACT

Background: The consumption rate of Monosodium Glutamate (MSG) in Indonesia remains high. Lemon is an antioxidant and neutralizer of free radicals which contains vitamin C and phytochemicals to prevent the long-term effects of MSG to pyramidal cells. This study aims to test the effect of oral administration of lemon juice (*Citrus limon*) to the number of pyramidal neuron cells.

Methodology: This experimental study employed 30 male white mice aged 2.5 to 3 months. Those mice were randomly divided into five control-groups: Normal Control (KN), Negative Control (K-) was treated with 4 mg/grBB MSG, Dose Group 1 (KD1) was treated with 3.33 ml/kgBB lemon juice, Dose Group 2 (KD2) was treated with 6.67 ml/kgBB lemon juice, and Dose Group 3 (KD3) was treated with 13.33 ml/kgBB lemon juice. Kruskal Wallis test was used to determine the difference in distribution between groups, followed with Post hoc Mann Whitney test.

Results: After 28 days of treatment, the average number of pyramidal neuron cells in dose group 1 (637 cells) was higher than in negative control (589.5 cells) ($p=0.078$). The average number of pyramidal neuron cells in dose group 3 (482,5 cells) was lower than in the negative control (589.5 cells) ($p=0.016$). The statistical result shown that there were groups with a significant difference in pyramidal cells number. Mann-Whitney analysis of pyramidal cells number had shown that there was a significant difference between group KD3 and KD1, KD3 and K (-), KD3 and KD2.

Conclusion: Lemon juice (*Citrus limon*) in precise dose has a beneficial effect to reduce the excitotoxic effect of MSG. Further studies is needed to validate the active compound and toxicity effect of lemon juice.

Keywords: Pyramidal neuron cells, monosodium glutamate, lemon (*Citrus limon*)

INTRODUCTION

Monosodium Glutamate (MSG) is one of the food flavor enhancers. Data from 2013 Indonesian Basic Health Research shows that flavor enhancer can be classified into high-risk food most consumed by Indonesian population. Four out of five Indonesians consume flavor enhancer more than once a day (77,3%) [1]. The glutamate in MSG physiologically used by the body as the main excitatory neurotransmitter found in the central nervous system in mammals and is involved in various normal brain functions, including cognition, learning, and memory function. The accumulation of an abundant amount of glutamate in the

synapse is excitotoxic for the brain [2]. Glutamate excitotoxicity triggers cell degenerations particularly in relation to pyramidal neuron cells [3].

One of the natural ways to prevent pyramidal neuron cell degeneration is to consume fruits with antioxidant properties, such as lemon. Lemon contains carbohydrates, fats, proteins, vitamins such as thiamine, riboflavin, niacin, pantothenic acid, folate, choline, and it is rich of vitamin C [4]. Lemon also contains various elements such as magnesium, potassium, zinc, and a number of phytochemical compounds such as tannins and flavonoids [4,5]. Flavonoid can function as a direct antioxidant and hinder free radicals, as well as having the capacity to modulate the activity of the enzyme and inhibit cell proliferation [4]. Antioxidants also now being looked upon as persuasive therapeutic against neuron cells degeneration, as they have capability to combat by neutralizing free radicals [6]. Antioxidant is further supported with antioxidant enzymes, e.g. superoxide dismutase, catalase, glutathione reductase and glutathione peroxidase those exert synergistic actions in removing free radicals [7]. Therefore, this study was conducted to observe the effects of the oral administration of lemon juice on the histopathology of pyramidal neuron cells of male white mice's cerebral cortex with Monosodium Glutamate treatment.

METHOD AND MATERIAL

Ethical Clearance approval No. 24/EC/FK/XI/2018 was obtained from the Ethics Committee of the Faculty of Medicine, Swadaya Gunung Jati University. This experimental study was conducted at *Laboratorium Pangan dan Gizi Pusat Antar Universitas* (PAU) Gadjah Mada University, Yogyakarta and Anatomical Pathology Laboratory of the Faculty of Medicine, Swadaya Gunungjati University, Cirebon from August 2018 to April 2019. Posttest-only control group design was used to examine the histopathology of pyramidal neuron cells in the cerebral cortex using male white mice (*Mus musculus*) as the research object.

Animal Protocol

Thirty mice (2.5-3 months old) weighing 20-40 gram were divided randomly into 5 groups: KN, K(-), KD1, KD2, and KD3. After 7 days of adaptation period, group K(-), KD1, KD2, and KD3 were given Monosodium Glutamate (MSG) treatment with the dose of 4 mg/grBW for 14 days. Later on, the treatment of MSG was stopped and the treatments for group KD1, KD2, and KD3 were continued with the treatment of lemon juice with the respective doses of: 3.33 ml/kgBW, 6.67 ml/kgBW, and 13.33 ml/kgBW for the next 14 days. MSG and lemon juice were given once a day in the afternoon using the gastric sonde. KN group was the Control Normal that was only fed normal food, K(-) group was Negative Control which mice were given Monosodium Glutamate (MSG) 4 mg/grBB treatment [3,8], the mice fed with MSG which have been observed experiencing the pyramidal neuron degeneration were given lemon juice of 3.33 ml/kgBW (KD1), 6.67 ml/kgBW (KD2), 13,33 ml/kgBW (KD3) [9].

Cerebral Cortex Histopathology

After 28 days of treatment, the mice were then terminated using cervical dislocation method. Necropsy was then performed for the cerebral cortex extraction. The formulation of the specimen of the cerebral cortex pyramidal neuron cell histopathology was processed with fixation, washing, dehydrating, clearing, impregnating, embedding, cutting, staining, and mounting in accordance to the previous study. Hematoxylin and eosin (H&E) were prepared to stain the cell section of every mouse in all groups [10]. Histopathology examination was analyzed using a binocular microscope and was measured in 5 fields of view with objective lens 400x.

Statistical Analysis

The group distribution differences in all groups of the histopathology of pyramidal neuron cells of mice's cerebral cortex were analyzed using the Kruskal-Wallis test, followed with Post Hoc Mann Whitney test.

RESULTS

Histopathology of the cerebral cortex

Microscopic analysis was done by counting pyramidal neuron cells in 5 viewing field of each H&E stained sections prepared from all groups (Fig. 1). Pyramidal neuron cells in dose group 1 had more cells than the negative control group, meanwhile, dose group 3 had fewer cells than the negative control group (Table 1).

Table 1 reveals the number of pyramidal cells from all five groups

Group	Amount average of pyramidal cells + SD	Minimum	Maximum
KN	534.5 ± 90.5	412	673
K (-)	589.5 ± 43.8	511	627
KD1	637 ± 90.42	453	715
KD2	531.5 ± 27.18	514	589
KD3	482.5 ± 51.98	428	586

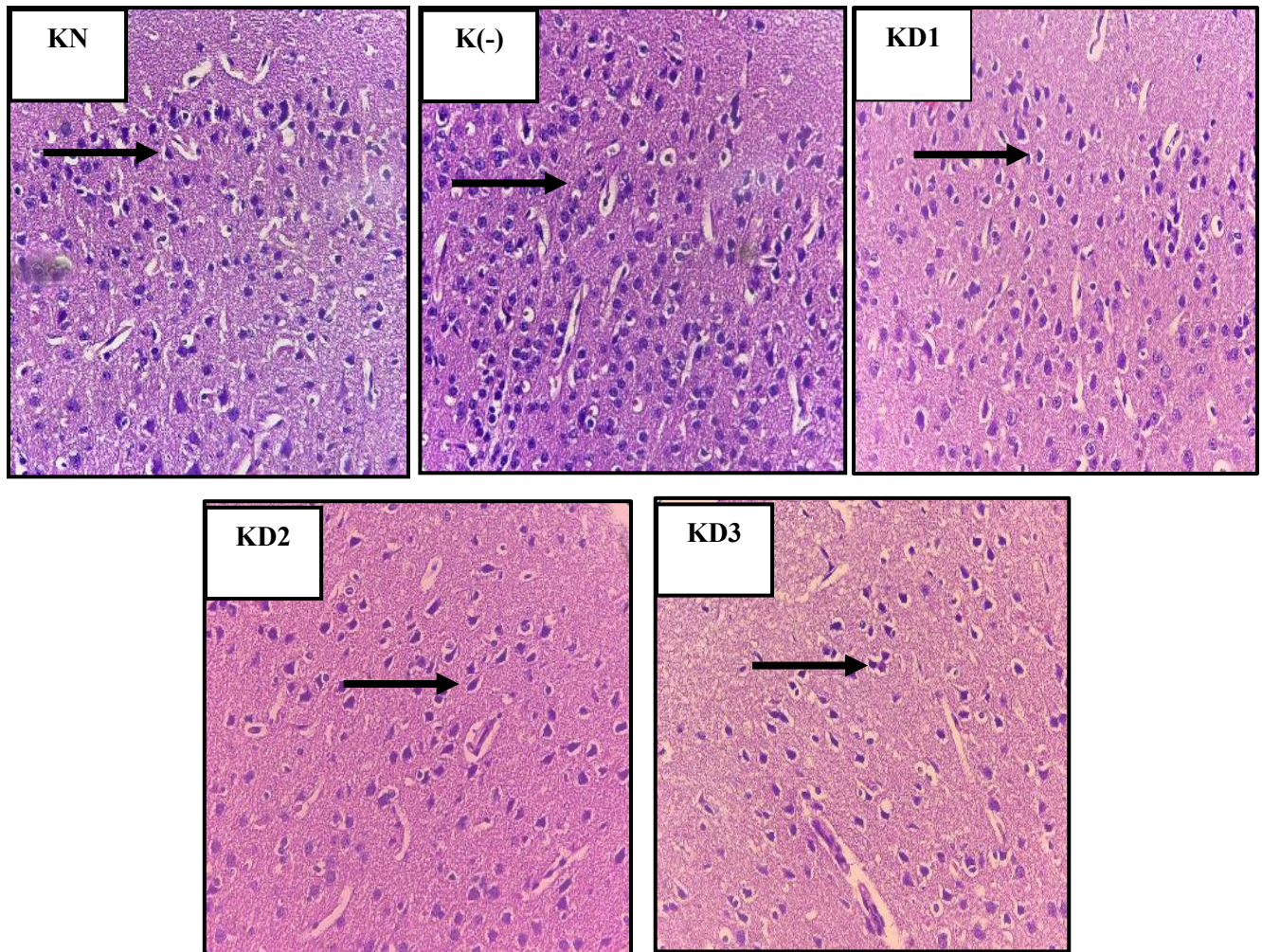


Fig. 1. H&E stained cerebral cortex sections of five groups after 28 days of treatment in objective lens 400x. KN was the normal control, K(-) was negative control treated with Monosodium Glutamate (MSG) 4 mg/grBW, KD1 was treated with MSG 4 mg/grBW and lemon juice 3.33 ml/kgBW, KD2 was treated with MSG 4 mg/grBW and lemon juice 6.67 ml/kgBW, and KD3 was treated with MSG 4 mg/grBW and lemon juice 13.33 ml/kgBW. Arrow showed pyramidal cells in the cerebral cortex.

The pyramidal cells observed in all groups were counted and compared using statistical analysis. The data distribution was not normal, thus Non-parametric statistical analysis (*Kruskall-Wallis* test) was used to see whether there is a significant difference in the number of pyramidal cells among the five groups. With Confidence Interval (CI) 95%, p -value = 0.026 had shown that there were groups with a significant difference in pyramidal cells number. Thus, *post-hoc Mann-Whitney* test was performed to see which pair of groups had a significant difference (Table 2). *Mann-Whitney* analysis of pyramidal cells number had shown that there was a significant difference between group KD3 and KD1, KD3 and K (-), KD3 and KD2, (p -value < 0.05).

Table 2. Mann- Whitney Test

	KD 3	KD 2	KD 1	K. (-)	K. No
KD 3	#				
KD 2	0.037	#			
KD 1	0.037	0.054	#		
K (-)	0.016	0.109	0.078	#	
K. No	0.200	0.873	0.109	0.423	#

p value < 0.05 which means significantly different

DISCUSSION

The Effects of Oral Administration Lemon Juice (Citrus lemon) Towards Pyramidal Neuron Cells of Male White Mice's Cerebral Cortex Treated with Monosodium Glutamate (MSG)

This research had shown that average number of pyramidal neuron cells of normal group (KN) are 534.5 cells and negative control (K-) are 589.5 cells, it means there are increasing number of cells on the group were given MSG. the previous studied by Simon H in 2013, showed there was an increase in the number of pyramidal neuron cells that exposed by MSG 5 mg/grBW for 4 weeks treatments. It can be indicated that it has occurred an excitotoxicity glutamate [3].

An increasing number of pyramidal cells in the cerebral cortex also appeared on group dose 3.33 ml/kgBW (KD1). This was caused by the antioxidant effects contained in the lemons, where antioxidants were able to stop or inhibit the oxidative damage caused by free radicals due to the induction of Monosodium Glutamate. The result was in accordance with the previous study conducted by Quita in 2016, where the treatment of lemon was able to protect the testicular tissue repair cells that had been induced by *cyclophosphamide* in mice [11].



The result of the study also showed that there was an increase in the number of pyramidal cells in the cerebral cortex of the negative (-) control group. It was due to the cessation of MSG treatment in the 14th to 28th day which caused the neuron cells to undergo cells regeneration in the next 14 days. This is consistent with the research conducted by Dayano in 2015, where the cessation of MSG treatment for 28 days caused the pyramidal cells to undergo cells regeneration involving glutamate and GABA neurotransmitter [9]. This regeneration is supported by the research conducted by Vicini S in 2008, where it was stated that glutamate and GABA were important substances in the neurogenesis process. Glutamate and GABA play an important role in proliferation, cell migration, and synapse formation in the forming of new neurons. Neurogenesis activity in the brain was reported to happen in the subventricular zone (SVZ) in the lateral ventricle and subgranular zone (SGZ) in the dentatus gyrus. In SVZ, GABA acts as the feedback regulator in the neuron cells formation and migration, meanwhile, in SGZ, GABA operates to regulate the cell differentiation process and synapse formation. Moreover, glutamate also has a role in cell migration and the formation of neuroblast for neurogenesis [12].

Different results were shown by dose groups of 6.67 ml/kgBW and 13.33 ml/kgBW which were given lemon juice for 14 days and termination of MSG treatment. There was lesser number of cells compared to both normal control and negative control. In the dose group of 6.67 ml/kgBW there were 531,5 cells, and in the dose group of 13.33 ml/kgBW with the least number, 482,5 cells. The lesser number of cells in the dose groups compared to normal and negative control was presumed to be related to the high level of citric acid contained in the lemon juice, which would reduce the performance of antioxidant GSH-Px enzyme. This was supported by a study conducted by Chen in 2014, which stated that the high level of citric acid was in line with the high level of MDA (*Malonyldialdehyde*). MDA is a lipid hydroperoxide formed from lipid peroxide due to an increase in free radicals. The increase of free radicals is caused because the high dose of citric acid decreases the performance of GSH-Px enzyme which works as H₂O₂ detoxification [13].

The lesser number of cells in the dose group of 6.67 ml/kgBW and 13.33 ml/kgBW compared to the normal and negative control groups may be related to the stress factor that was experienced by the mice during the treatment, this attunes with the study conducted by Dayono in 2015, wherein a stressful state, adrenal gland would produce adrenaline and release cortisol. Constant stress caused cortisol level to remain at high and can damage the hippocampus. This stress condition can also be experienced by the research mice related to the physical treatment when giving the treatment with feeding tube, weighing the research animal, picking up the research animal for the treatment admission, the environmental condition of the research animal, and the interaction between research animals in the cage that consists of 6 research animals. The stress condition can cause a decrease in the speed of blood flow and vasomotor reactivity so that the brain metabolism can be disrupted and will affect the brain neurons, including pyramidal cells in the hippocampus through an ischemic cascade [14].

The limitations of this study was researchers only looked of the numbers without searching for further the morphology of pyramidal neuron cells, the researchers did not terminating mice in K (-) on the day the MSG treatment was stopped, so that it could be one of the biases for the results of the study. Further studies is needed to validate the active compound and toxicity effect of lemon juice and researching the comparasion between the morphology of normal and degenerative pyramidal neuro cells.

CONCLUSION

Lemon juice (Citrus limon) in precise dose has a beneficial effect to reduce the exitotoxic effect of MSG. further studies is needed to validate the active compound and toxicity effect of lemon juice.

CONFLICT OF INTEREST DECLARATION

The authors declare that there is no conflict of interest regarding the publication of this paper

REFERENCES

- [1]. Badan Penelitian dan Pengembangan Kesehatan Kementerian Kesehatan RI. Riset Kesehatan Dasar (RISKESDAS) Tahun 2013.
- [2]. Razali R. Monosodium Glutamat (MSG) dan Efek Neurotoksisitasnya Pada Sistem Saraf Pusat. Banda Aceh: Universitas Syiah Kuala.
- [3]. Simon H, Hexanto M, Dwi P. Pengaruh Pemberian Monosodium Glutamat peroral terhadap Degenerasi Neuron Piramidal CA1 Hipokampus pada Tikus Wistar. *Medica Hospiralia*. 2013; 1(3) : 175-181.
- [4]. Pakaya D. Peranan Vitamin C Pada Kulit. *Medika Tadulako, Jurnal Ilmiah Kedokteran*. 2014; 1(2):45-52.
- [5]. Campêlo LML, Fabricio CMG, Chistiane MF, Rivelilson MDF. Antioxidant activity of Citrus limon essential oil in mouse hippocampus. *Informa Healthcare*. 2011; 49(7): 709–715.
- [6]. Uttara B, Ajay VS, Paolo Z, R.T. Mahajan. Oxidative Stress and Neurodegenerative Diseases: A Review of Upstream and Downstream Antioxidant Therapeutic Options. *Current Neuropharmacology*. 2009; 7(1) : 65-74.
- [7]. Yun-Zhong, F., Sheng, Y., Guoyao, Wu. (2002) Free radicals, antioxidants, and nutrition. *Nutrition*, 18, 872- 879.
- [8]. Zulfiani, Syarifudin I, Salomo H. Pengaruh Pemberian Vitamin C dan E terhadap Gambaran Histologis Ginjal Mencit (*Mus musculus L.*) yang Dipajankan Monosodium Glutamat (MSG). (Skripsi). Medan: Universitas Sumatera Utara. 2013.
- [9]. Wijaya YA. Daya Analgesik Sari Buah Jeruk Lemon (*Citrus Limon (L.) Burm. F.*) pada Mencit Putih Betina. (Skripsi). Yogyakarta: Universitas Sanata Dharma. 2008.
- [10]. Muntiha, Mohamad. Teknik Pembuatan Preparat Histopatologi Dari jaringan Hewan dengan Pewarnaan Hematoksilin Dan Eosin (H&E). Bogor. 2001.
- [11]. Quita SM. Evaluation of lemon fruit extract as an antioxidant agent against histopathological changes induced by cyclophosphamide in the testes of albino mice. *Electronic Physician*. 2016; VIII (1): 1824-1831.
- [12]. Dayono B, Heru FT, M. In'am I. Histologi Sel Piramidal Hipokampus Tikus Putih Pasca Penghentian Pajanan Monosodium Glutamat Peroral. *Jurnal Vokasi Kesehatan*. 2015; 1(4): 124-130.
- [13]. Vicini S. The role of GABA and glutamate on adult neurogenesis. *J Physiol*. 2008; 586(16): 8-377.
- [14]. Chen X, Qiongxia LV, Yumei L, Weng D. Study on injury effect of food additive citric acid on liver tissue in mice. *Cytotechnology*. 2014; 66: 275–282.